Differential vulnerability of hippocampal microstructure in 5xFAD mouse model of Alzheimer's Disease: A dMRI study

Syed Salman Shahid[1,2], Bruce T. Lamb[1,3], Adrian L Oblak[3,4] and Yu-Chien Wu[1,2,3]

[1]Center for Neuroimaging, Department of Radiology and Imaging Sciences, Indiana University School of Medicine, Indianapolis, [2]Indiana Alzheimer's Disease Research Center, Indiana University School of Medicine, Indianapolis, [3]Stark Neuroscience Research Institute, Indiana University School of Medicine, Indianapolis, [4]National Centralized Repository for Alzheimer's Disease and Related Dementias (NCRAD), Indianapolis

INDIANA UNIVERSITY SCHOOL OF MEDICINE

IADRC STARK

Background

Hippocampal subfields exhibit differential vulnerabilities to Alzheimer's disease (AD) associated pathologies. These pathological processes extensively attenuate the structural and functional interconnectivities of the subfields and may explain the association between hippocampal dysfunction and cognitive decline. Abnormal accumulation of beta-amyloid (Aβ) in extracellular neuritic plaques is considered a primary hallmark of AD. Histopathological studies suggest region-specific accumulation of Aβ in hippocampal subfields. The aim of the current study is to understand the subfield-specific in-vivo microstructural changes in hippocampus due to Aβ load in 2.5 months old 5xFAD mouse model of AD.

Abbreviations:

Aβ: β-amyloid; AD: Alzheimer's disease; CA1: cornu ammonis 1; CA2: cornu ammonis 2; CA3: cornu ammonis 3; DG: dentate gyrus; GLM: general linear model; DWI: diffusion weighted Imaging; dMRI: diffusion magnetic resonance imaging; EPI: echo planar imaging; MRI: magnetic resonance imaging; NODDI: neurite orientation dispersion and density imaging; ODI: orientation dispersion index; TE: echo time; TR: repetition time; VF_{EC}: extracellular volume fraction; VF_{IC}: intracellular volume fraction; VF_{ISO}: volume fraction of isotropic water diffusivity

Material and Methods

2.5-month-old male 5xFAD and age-matched littermate controls were used in this study. DWI and anatomical images were acquired on a horizontal bore 9.4T Biospec micro-MRI system equipped with a ^{1}H cryogenic surface coil. 2D T2-weighted anatomical images were acquired using the following parameters: TE/TR=43.67/7500 ms, voxel size=117x117x250 μm^3 and number of slices=20. DWIs were acquired using multi-shot dual-spin-echo EPI sequence using following parameters: TE/TR=34.78/3000 ms, voxel size=117x117x250 μm^3, number of slices=20, 5 b0 per shell, 12 diffusion encoding direction for b=650, 60 for b=1200 and 80 for b=2500 s/mm^2. T2-W images were nonlinearly registered to Badhwar hippocampal atlas. Hippocampal subfields (CA1, CA2, CA3, DG and Subiculum) in atlas space were transformed to individual T2W space and then linearly transformed to DWI space. Multi-compartment microstructural imaging was performed using Cortical-NODDI. Volume fraction of isotropic water diffusivity (VF_{ISO}) and intracellular volume fraction (VF_{IC}) maps were calculated. The regional mean values (VF_{IC} and VF_{ISO}) of individual subfields were extracted and used in general linear model (GLM) for group-comparisons.

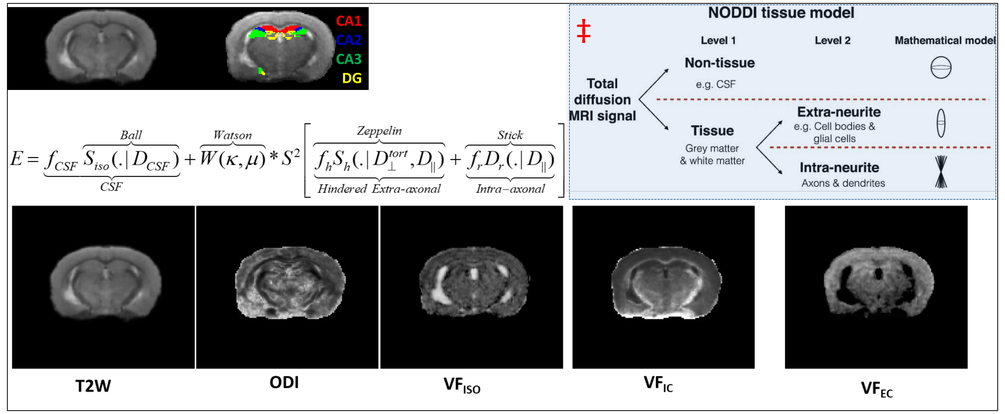

Figure 1: Animal/tissue specific NODDI derived microstructural parametric maps. In NODDI model, intracellular intrinsic parallel diffusivity of 1.1mm^2/s was used.

‡ Source: https://doi.org/10.1016/j.neuroimage.2016.01.046

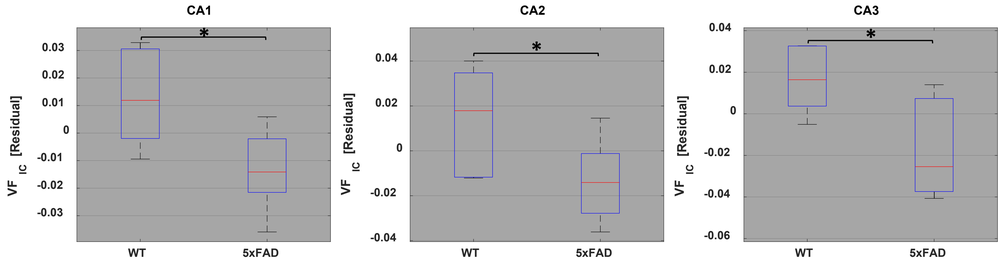

Figure 2: Group differences of tissue specific NODDI derived intracellular volume fraction (VF_{IC}) in hippocampal subfields (CA1, CA2 and CA3) among WT and 5xFAD. The comparison was conducted using general linear model with normalized hippocampal volume as covariate. * denotes $p < 0.05$.

Number of animals per group = 5

Results

The results of the study suggest group-level differences between control (N=5) and 5xFAD (N=5) mice in cornu ammonis regions. Compared to 5xFAD mice, intracellular volume fraction (VF_{IC}) in littermate control mice was significantly higher in CA1 ($p<0.05$; $d=1.47$), CA2 ($p<0.05$; $d=1.11$) and CA3 ($p<0.05$; $d=1.54$) regions.

Conclusion

The study demonstrates the importance of utilizing tissue-specific microstructural imaging in detecting Aβ associated microstructural alterations in multiple hippocampal subfields. This study demonstrates that Aβ alters the hippocampal microstructure, specifically the cornu ammonis regions during the early stages of the pathology. study also suggests on the differential effect of Aβ pathology on hippocampal microstructure.

Contacts

Syed Salman Shahid – shahids@iu.edu
Bruce T. Lamb - btlabm@iu.edu
Adrian L Oblak - aoblak@iupui.edu
Yu-Chien Wu - yucwu@iu.edu