

CINEUROGRAPHY

ROBERT A. GARRETT AND EUGENE C. KLATTE

From the Departments of Urology and Radiology, Indiana University School of Medicine, Indianapolis Ind.

Cineradiography became a practical maneuver with the development of fluoroscopic image intensification described by Coltman in 1948.¹ Prior to that date, excessively large doses of x-ray were necessary to achieve motion picture images sufficiently sharp to be diagnostic. Adaptation of the motion picture camera to the fluoroscope was reported in detail by Ramsay and his co-workers² in the same year. Muellner,³ studying the mechanisms of micturition, employed fluoroscopy, recording key phases in conventional static radiographs. Kjellberg, Ericsson and Rudhe,⁴ in their excellent monograph, the Lower Urinary Tract in Childhood, utilized the biplane serial changer to evaluate motion. Cineradiography of the bladder and urethra was described by Benjamin⁵ and by Hinman, Jr.⁶ As equipment has become available, wider usage in urology has followed. Excretory urography, retrograde pyelography, antegrade urography, cystography and particularly voiding cystourethrography in all but the obese patient can be successfully visualized with this technique.

TECHNICAL FACTORS

Equipment. Five inch Westinghouse and Phillips image intensifiers were adapted to

This study was supported by the Riley Memorial Foundation, James Whitcomb Riley Hospital for Children, Indianapolis, Ind.

¹ Coltman, J. W.: Fluoroscopic image brightening by electronic means. *Radiology*, **51**: 359-366, 1948.

² Ramsay, G. H. S., Watson, J. S., Jr., Steinhäusen, T. B., Thompson, J. J., Dreisinger, F. and Weinberg, S.: Cinefluorography. *Radiology*, **52**: 684-690, 1949.

³ Muellner, S. R. and Fleischner, F. G.: Normal and abnormal micturition: A study of bladder behavior by means of the fluoroscope. *J. Urol.*, **61**: 233-243, 1949.

⁴ Kjellberg, S. R., Ericsson, N. D. and Rudhe, U.: The Lower Urinary Tract in Childhood. Chicago: Yearbook Publishers, Inc., 1957.

⁵ Benjamin, J. A., Joint, F. T., Ramsay, G. H., Watson, J. S., Weinberg, S. and Scott, W. W.: Cineradiographic studies of bladder and urethral function. *Trans. Am. Assn. G. U. Surg.*, **66**: 43-53, 1954.

⁶ Hinman, F. Jr., Miller, G. M., Nickel, E. and Miller, E. R.: Vesical physiology by cineradiography and serial roentgenography. *Radiology*, **62**: 713-719, 1954.

standard fluoroscopic tables. A special sling was constructed which facilitated positioning for voiding cystourethrography (fig. 1). Five millimeters of aluminum filter were used. Cineradiography was performed at 8 to 15 frames per second. The average technical factors for a 6-year-old child are 70-80 KV at 2 to 6 MA. This would deliver 1-5 roentgens per minute to the skin of the patient. The method of recording dose is a varied one. At the low exposure dose rate with diagnostic radiological equipment, the danger of the injury to the skin or other organs is negligible. It is now accepted that all radiation to the gonads is objectionable. In order to evaluate the gonadal dose with cineurography, it would seem best to compare it to the gonadal dose obtained with other accepted diagnostic radiological procedures. A papier-maché phantom of a 6-year-old child was constructed and the radiation gonadal dose measured for various diagnostic procedures. For cineurography, a 30 second exposure was made while scanning the bladder and both upper tracts. A second 30 second exposure was then made over the bladder neck with the child in a 45 degree left anterior oblique position. These gonadal dose measurements are recorded in table 1. It will be seen that the gonadal dose was less with cineurography than with accepted diagnostic radiological procedures.

All cineurographic examinations were recorded on 16 mm. Linagraph Shellburst film. While it is true that the larger film size of 35 mm. film may give a better inherent definition, the unsharpness factors of the image intensifier are such that this is difficult to perceive on projection. Film cost and processing, storage, and projection problems are significantly less with 16 mm. film.

An analyzing projector is essential for the proper interpretation of cineurography. Two units designed for this work are the perceptoscope and the Watson-Weinberg modification of the kodak analyst. Both units allow slow motion projection and prolonged single frame analysis without danger of burning the film.

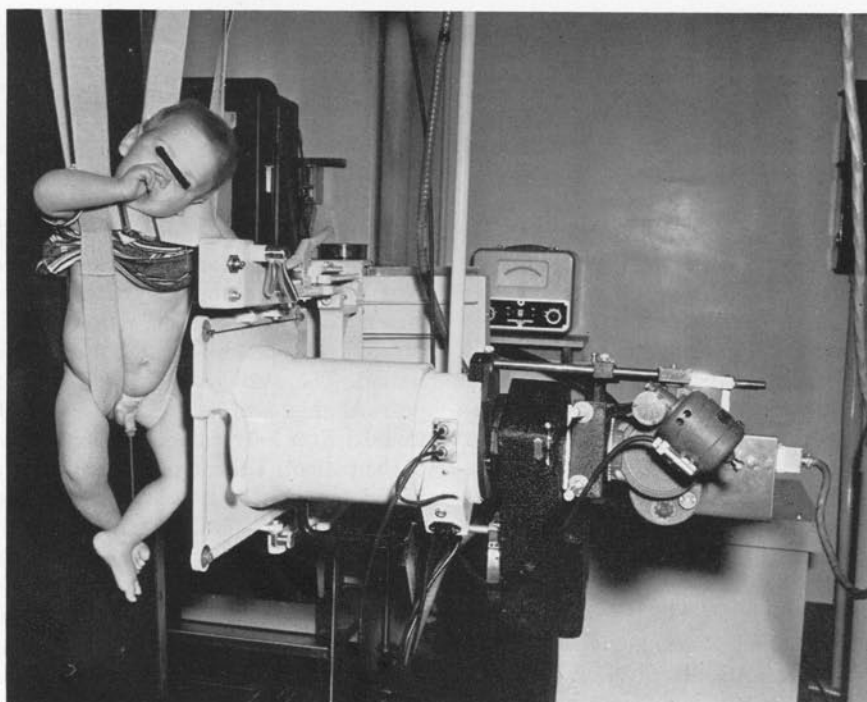


FIG. 1. Vertical sling for suspension of infants during cineurography, between fluoroscopic table on left and fluoroscopic tube with camera on right.

ADVANTAGES

There seems little doubt that, in general, motion studies of motile viscera have greater diagnostic yields than conventional static films. Not only are urine transport dynamics visualized, but by single frame study, phase positional changes are evident. Obstructive lesions may be elucidated which might otherwise be poorly appreciated. Since the use of this modality, momentary ureteral reflux undetected by conventional cystography has been seen. Hydro-ureter may be evaluated as to tonicity and urine transport capability (fig. 2). Ureteral calculus manipulation and, under special circumstances, ureteral catheterization might be carried out under the fluoroscopic component alone advantageously. Cineurography may yield valuable information in the incontinent patient.

DISADVANTAGES

Cost and cumbersome characteristics of the equipment are major deterrents to common practice. Both may be expected to improve in coming years. Those features notwithstanding,

TABLE 1. *Gonadal dose in milliroentgens (6-year-old child)*

Examination	Males	Females
Voiding cinecystourethrography (60 sec.).....	180	155
Voiding cystourethrography (2 radiographs).....	1100	620
Intravenous urogram.....	825	510
Barium enema.....	475	410
Lumbosacral spine.....	1275	790

efforts in our departments are being directed to the adaptation of this equipment to the cystoscopic table. With proper selection of clinical material, radiation dosage should not be considered excessive for information gained.

SUMMARY

Cineurography offers an additional modality for investigation of the urinary tract. Dynamics of these motile viscera may be better evaluated than through other conventional methods. While

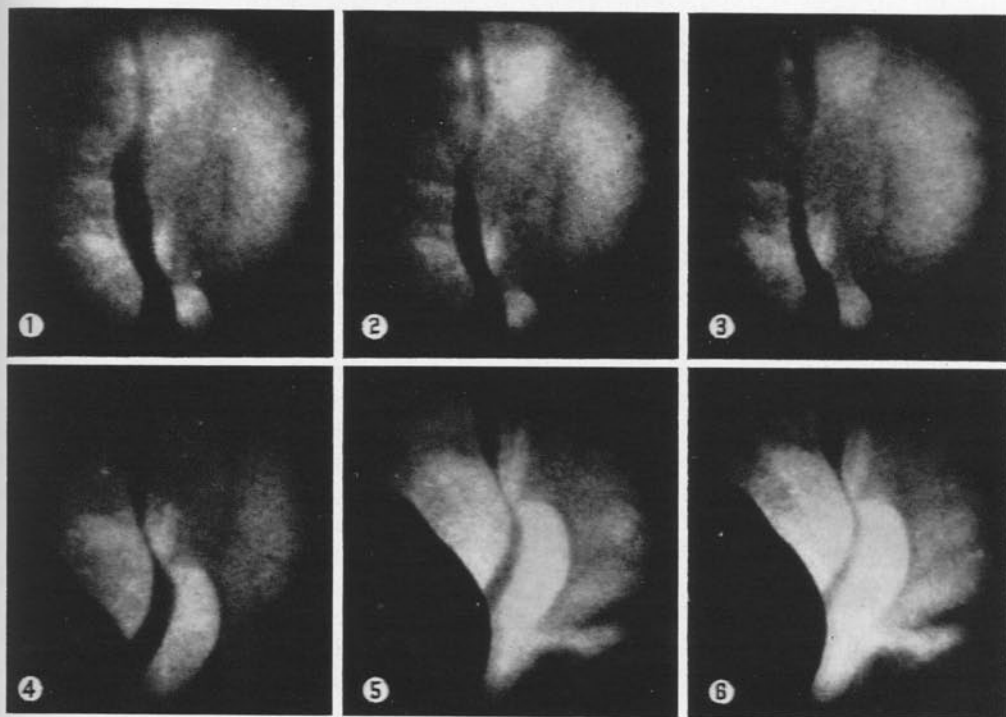


FIG. 2. Six serial frames taken from 3 second sequence of left ureteral peristalsis. Note progression of contraction wave down the lower third of ureter.

the apparatus necessary for these studies is expensive and cumbersome, improvement in these areas may be confidently expected. Advantages, disadvantages and certain technical

features bearing on this technique are discussed. Radiation dosage is not considered excessive when care is taken in selecting suitable clinical material and in the proper use of the apparatus.